

# Effects on movement of surgical incisions into the human spinal cord

P. W. Nathan

The National Hospital for Neurology and Neurosurgery, London, and the Radcliffe Infirmary, Oxford

Correspondence to: P. W. Nathan, The National Hospital for Neurology and Neurosurgery, Queen Square, London WC1N 3BG, UK

## Summary

In 44 patients having cordotomies for relief of the pain of cancer, a correlation was made between the location and extent of the incision in the spinal cord and the motor state. Post-mortem histological examination of the spinal cord was carried out in all areas. An incision cutting through one anterior quadrant of the cord at any segmental level could be made without causing any disturbance of motility. An incision in the thoracic segments cutting through the anterior half of the cord could be made without causing any disturbance of motility. This fact implies that tracts in the posterior half of the cord can supply the input from the brain necessary for the maintenance of functions normally mediated by tracts in the anterior half of the cord. The more posterior the incision reached in the posterolateral column, the greater were the defects in motility. A large unilateral lesion dividing most of the lateral corticospinal tract, and the descending fibres anterior to it, caused flaccid paralysis of the ipsilateral lower limb. Voluntary movements started to return within 5 h. An incision in the thoracic cord cutting through one lateral corticospinal tract and 85–90% of the opposite tract and reticulospinal fibres anterior to that tract caused total paralysis of the lower limbs. Recovery ensued over

2 months so that the patient eventually walked, though with severe spastic paraparesis. Recovery of some flexor and extensor movements of the ipsilateral fingers and toes occurred within 6 h of an incision being made in the upper cervical cord that divided the lateral corticospinal tract unilaterally. Division of only the anterior fibres of the lateral corticospinal tract above the cervical enlargement did not affect the motility of the ipsilateral upper limb. It is concluded that in the more cranial segments of the spinal cord, corticospinal fibres destined for the upper limb are in the more posterior part of the tract. Correlation of the clinical with the histological evidence of a lesion of the lateral corticospinal tract was carried out. When it was deduced on the clinical evidence that the tract was damaged, this was always found to be correct. On the other hand, the tract might show histological evidence of damage without manifesting any evidence of a lesion. The Babinski response was found, in general, to occur with lesions of the lateral corticospinal tract and not with lesions elsewhere in the cord. But a normal response could be associated with a large lesion of this tract; and a transient Babinski response could occur with anterior lesions.

**Key words:** spinal cord lesions; motility

## Introduction

In this paper, evidence is presented on the defects in motility and the recovery that occur following various incisions at various levels of the spinal cord.

In all cases, histological examination of the spinal cord was undertaken and so the extent and location of the incisions are known. The effects of the operations are considered first with regard to the paresis and secondly with regard to the ensuing recovery of motility. All reference to lesions of tracts means tracts within the spinal cord.

It is surprising that there is a necessity for a study such as

this for, although clinico-anatomical correlation is the foundation of neurology, it is seldom undertaken. One reason may be that the site and extent of a lesion is only one of the facts: patients with the same lesions may not show the same motor defects. This lack of correlation is more marked than it is in the sensory sphere; for the sensory examination usually allows one to define the location of the lesions in the anterior and lateral columns correctly.

The location of the lateral corticospinal tract throughout the spinal cord was published by Nathan *et al.* (1990): when, in

the present paper, the position of tracts is related to that of the lateral corticospinal tract, reference is being made to the evidence presented in that paper.

## Patients

Forty-four patients, aged 21–58 years, who had cordotomies for the relief of pain of cancer, were studied. As there are so many cases, 10 illustrative cases are presented; though the conclusions are drawn from the entire group.

In many of the patients, the tumour was invading the peripheral nerves and nerve roots. When the posterior roots were invaded, there was degeneration of fibres in the posterior columns, but not in other tracts of the cord. This degeneration is seen in some of the figures. The effects of the invasion of peripheral nerves and roots on motility were assessed before and repeatedly after the cordotomy. In some patients, the destruction of nerves or nerve roots caused severe and progressive paresis; these cases were not included in this study. In other cases, the immediate effect of the cordotomy was obvious as it was not present before the operation and was present immediately after it.

The case numbers are the same throughout all papers by Nathan and Smith.

## Methods

### Clinical

The main motor functions assessed were the patients' ability to use their upper limbs and to walk.

Muscle strength was graded on the Medical Research Council Scale (MRC) (1943): 0 = no contraction; 1 = flicker or trace of contraction; 2 = active movement, with gravity eliminated; 3 = active movement against gravity; 4 = active movement against gravity and resistance; 5 = normal power.

Standard clinical neurological examinations were made before the cordotomies and from the day of the operation until a few days before the patients died. The patients' ability to control lower limbs was recorded in most cases by the ability to describe circles with the feet while sitting on a high chair, with legs hanging. A small electric bulb was attached between the first and second digit and recording was made in the dark.

### Histological

The cords were fixed in 10% buffered formol saline. In all cases the majority, and, in some cases, all spinal segments were examined histologically. Each segment was identified and cut transversely just cranial to the insertion of the most cranial nerve roots. This plane is taken arbitrarily as indicating the cranial limit of each segment.

The segments were mostly divided into several blocks, which were processed by different staining methods. The majority of blocks were embedded in celloidin; some wax-embedded and some frozen sections were also prepared. A wide range of histological methods was applied. Extensive use was made of

the Marchi method and of myelin staining, including Weigert, Pal, Loyez, luxol fast blue with cresyl violet. Other stains used were phosphotungstic acid haematoxylin, Häggqvist, Grös, Bielschowsky, Nauta, Marsland, Glees and Erikson (original method and modifications), haematoxylin and eosin, haematoxylin and van Gieson, thionin, Victoria blue and Scharlach R.

## Results

The effects of the lesions will first be considered with regard to impairment of motility and then with regard to recovery. The cases are presented under Groups 1–6, based on the location of the incisions.

### Group 1: bilateral incisions dividing many descending tracts

This group consisted of 18 patients, 15 female and three male, including three patients in whom two unilateral cordotomies were carried out. The patients in this group had very large incisions caudal to the cervical enlargement which divided most of the lateral corticospinal tract as well as a great many fibres in the lateral and anterior columns.

A typical example of motor defects following a large bilateral cordotomy is Case 93 (Fig. 1). After the operation, the patient was unable to sit without support, stand or walk. In the right lower limb minimal movements of the hamstrings and toes were possible. The movements of the left lower limb were slightly more extensive.

On the right side of the cord, the descending fibres that survived were those of the anterior corticospinal tract and of the medial longitudinal fasciculus, reticulospinal fibres of the anterior column and possibly fibres of the lateral vestibulospinal tract.

On the left, ~20% of fibres of the lateral corticospinal tract survived, and, in the anterior column, about a half of the fibres of the anterior corticospinal tract and half of those of the medial longitudinal fasciculus survived.

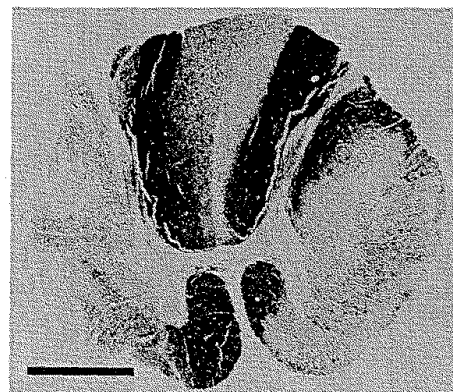

Fig. 1 Case 93. Weigert Pal preparation: pallor indicates degeneration. Cordotomy incision at T2. Bar = 2 mm.

### Recovery

Recovery following such large lesions was minimal. Although the patients were neither able to sit nor stand, minimal movements of the lower limbs returned.

### Group 2: large unilateral incisions dividing most of the ipsilateral descending tracts

This group consisted of 12 patients, seven female and five male, including three patients in whom there was later another contralateral cordotomy. The large incisions into one side of the cord that divided almost all of the lateral corticospinal tract together with the lateral column and most of the anterior column caused flaccid paralysis of the ipsilateral limbs. Although there was variability from case to case, the amount of immediate paralysis of the ipsilateral limbs depended on the extent of damage to the lateral corticospinal tract.

Figure 2 shows the incision at C2 on the left in Case 80. It divided many descending tracts including the lateral corticospinal tract.

Immediately after the operation there was total paralysis of the ipsilateral upper and lower limbs for 5 h, after which voluntary movements began to appear.

There were four patients who had operations at the same level, but in which the incision was smaller and divided only

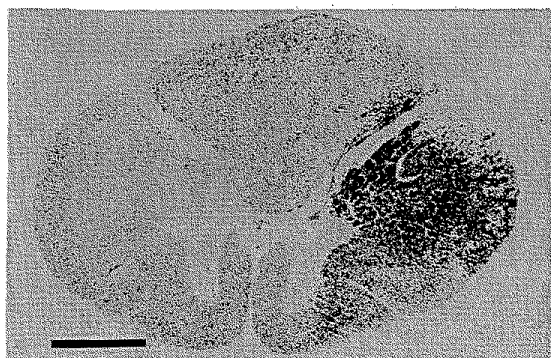


Fig. 2 Case 80. Marchi preparation: black staining indicates degeneration. Cordotomy incision at C2. Bar = 2 mm.

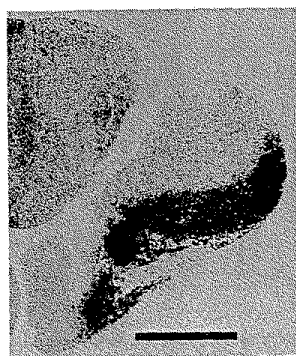


Fig. 3 Case 39. Marchi preparation. Cordotomy incision at C4-C4. Bar = 2 mm.

the anterior quarter of the lateral corticospinal tract. In none of these was motility of the upper limb affected. An example is Case 39 (Fig. 3).

These cases provide evidence that corticospinal fibres destined for the upper limb lie posterior to the incision shown in Fig. 3.

### Recovery

In a unilateral lesion dividing most of the lateral and anterior columns including the lateral corticospinal tract, recovery from the hemiplegia started within hours. In Case 80, 4 h 45 min after the incision was made, the patient moved his ipsilateral fingers. Five and a half hours after the incision, he moved the ipsilateral foot and toes and 10 h after the incision he could flex the ipsilateral upper and lower limbs, raising the knee from the bed. Thirty hours after the operation he could abduct the left upper limb slightly, flex and extend the forearm and could slightly extend the hand on the forearm. By 3 days after the operation he could make very slow and small movements of the hand and digits.

From the onset, the ipsilateral limbs were flaccid and tone remained fairly flaccid throughout the remaining 47 days of the patient's life; deep reflexes never returned. On the fourth day after operation, the left plantar response consisted of small indeterminate movements; the right response was the typical Babinski response. It became normal over the course of a few days. Three to 4 days before death, both plantar responses were Babinski responses.

Fourteen days after the operation, the patient could stand; he was able to walk, with someone supporting him on the left side. By 18 days after operation, movements of the left upper limb had become more extensive, he could place the left hand on the opposite shoulder and could carry out normal movements of the hand, fingers and thumb, but the movements were slow and feeble and required much effort. Within a few days he could walk without a stick but with a typical hemiplegic gait. It took an abnormally long time to start movements and movements were slow throughout their course. When he tried to perform individual movements of parts of the limbs, he could not restrict the movements to a part, such as the foot without the leg. Movements were crude and clumsy.

In Case 39 in which the incision extended less far posteriorly, recovery of walking occurred quickly. By 3 weeks after the operation, this patient could walk up two flights of stairs, though the left lower limb felt weaker than the right and he felt it would flex and let him down. At this time, when he repeated flexion and extension movements of the foot while sitting, he found the left limb felt stiff and movements were less extensive than those of the right foot.

### Group 3: a unilateral incision anterior to the equatorial plane passing through the central canal, dividing one anterior quadrant or anterolateral column of the cord

This group consisted of five patients, one female and four male. The term 'equatorial plane' is used to describe a horizontal line

drawn from one side of the cord to the other through the central canal. This line is used to divide the cord antero-posteriorly and also to relate incisions to the lateral corticospinal tract. The relationship of this tract to the plane varies at different levels. Nathan *et al.* (1990) concluded that the lateral corticospinal tract spreads anterior to this plane from C3 to C8. Thus incisions anterior to the plane divided fibres of the tract at that level but not cranial and caudal to these segments.

There were two cases with a unilateral incision anterior to the equatorial plane, dividing the entire anterior quadrant of the cord. One of the patients, Case 44 (Fig. 4), noticed that his leg on the side of the incision in the cord felt stiff on first getting up after the operation. This was the only change in motility that he noted. The other patient with an identical incision had no subjective defects whatsoever. He walked and went up and down stairs on the 10th day after operation. The patients in whom the incisions did not reach the midline and so had smaller incisions walked and went up and down stairs within 2 weeks of the operation.

#### **Group 4: a bilateral incision anterior to the equatorial plane**

This group consisted of four patients, all male. A bilateral incision below the cervical enlargement anterior to the equatorial plane effectively divided the anterior half of the cord. In three patients it caused no motor defects. In a fourth patient, the only abnormal feature was a Babinski response on some occasions.

The cord of a typical case without any disturbance of motility is shown as Fig. 5 (Case 51). In this case, there had been two bilateral operations, the first one at T5 and the second one at T2 on the right; the second bilateral operation was carried out 84 days after the first. Both incisions cut through the anterior half of the cord. There was no damage to the lateral corticospinal tract on one side and minimal damage on the other. When the patient returned home after the operation, it was noted that 'No patient having a cordotomy has had as few motor defects as this patient. His lower limbs were perfect after both operations and he was up and about within a week.'

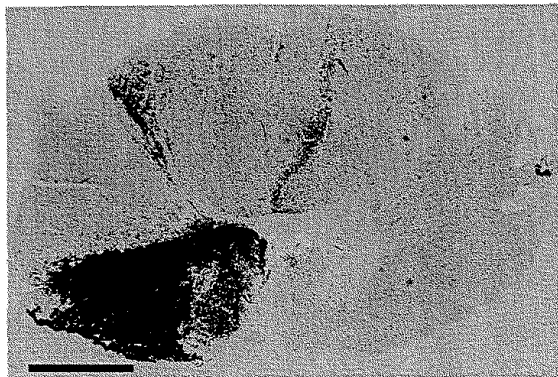


Fig. 4 Case 44. Marchi preparation. Cordotomy incision at C1-2. Bar = 2 mm.

The control of the lower limbs 3 weeks before and 4 weeks after the operation is shown by the circles performed by this patient (Fig. 6). These circular movements could be performed only by patients in whom there was no disturbance of motility. It is seen in this figure that the movements were performed identically before and after the operation.

Another of these patients ran up and down stairs within 4 weeks of the operation. In another patient the incisions extended posterior to the equatorial plane and impaired the control of micturition, but the patient could walk and go up and down stairs.

#### **Group 5: unilateral incision dividing a large part of the posterolateral column**

There was just one patient, male, in this group. The posterolateral incision caused complete or all but complete flaccid paralysis of the ipsilateral limbs, but the complete paralysis might last only for a few hours. A typical example

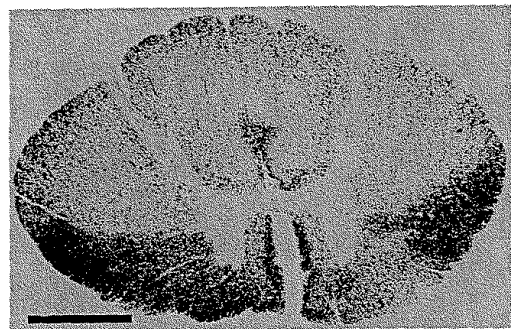


Fig. 5 Case 51. Marchi preparation. Cordotomy incisions at T4 and T5 on left, T2 and T5 on right. Bar = 2 mm.

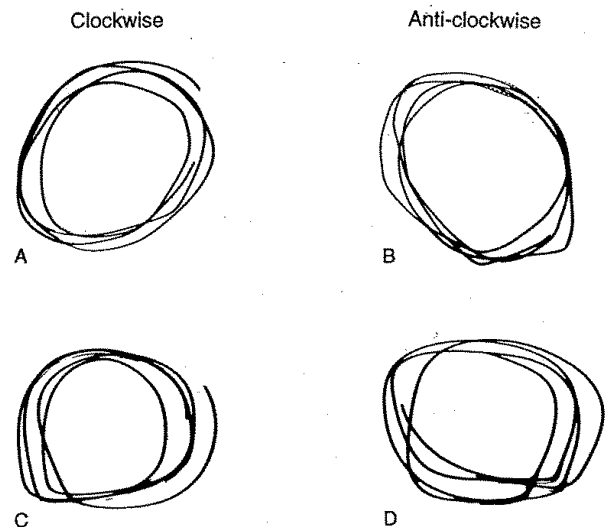


Fig. 6 Case 51. Traces of circular movements of right foot: A and B, 3 weeks before cordotomy; C and D, 4 weeks after cordotomy.

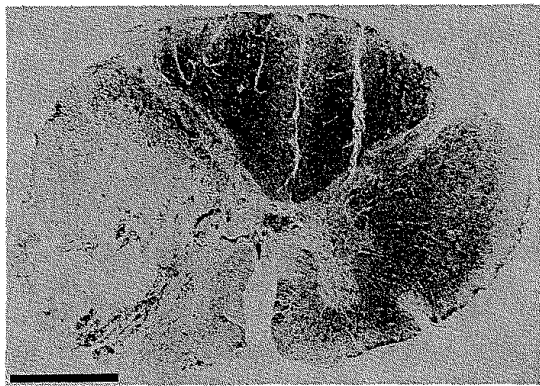
is Case 64 (Fig. 7). Three hours after the incision was made at the C2–3 segment, the upper limb moved in response to pinprick and 6 h later the limb moved to command.

When the incision was less posterior than that of Case 64, the amount of motor defects depended on how much of the lateral corticospinal tract was divided. The more posterior the incision, the more complete was the classical picture of hemiplegia. There was weakness and decreased resistance to passive movements at first, movements were slow in starting and throughout their course, and there was difficulty in fractionating movements of the foot and toes.

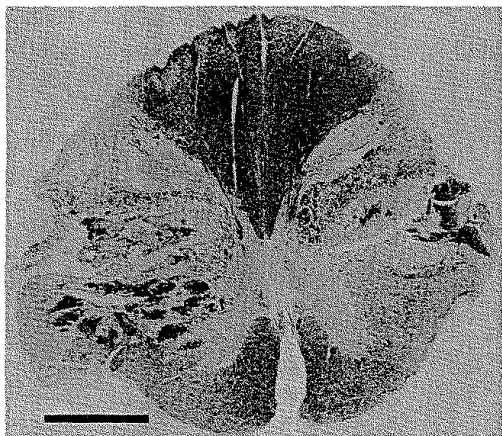
With less damage to the anterior fibres of the lateral corticospinal tract, paresis was usually less severe. Movements were likely to be weak and tone increased. Tendon reflexes were increased and in most cases there was a Babinski response.

### Recovery

There was early recovery from the disturbances of motility caused by a large unilateral posterolateral incision. Visible



**Fig. 7** Case 64. Haematoxylin and van Gieson preparation; pallor indicates degeneration. Cordotomy incision at C2–3. Bar = 2 mm.



**Fig. 8** Case 108. Loyez and neutral red preparation. The damage to the cord at 6 days' survival is shown by the pallor and the islands of dark staining, indicating haemorrhage. Cordotomy incision at C1–2. Bar = 2 mm.

movements of the muscles of the ipsilateral lower limb occurred within 48 h. Walking and going up and down stairs usually occurred within 2–3 months. Usually the tendon and plantar reflexes eventually became normal.

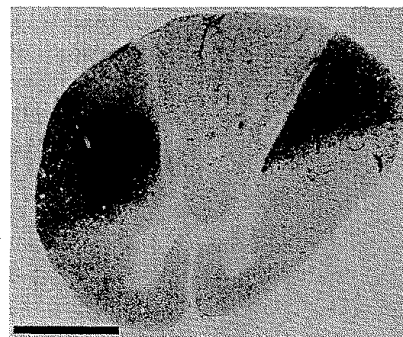
Even when a large incision divided the whole of the lateral corticospinal tract and the lateral column—an example is Case 93 (Fig. 1) right side—the patient was able to flex the thigh on the pelvis, raising the limb from the bed, within 2 weeks of the operation. By 70 days, there was full power in all muscles of the lower limb, except for toe movements, which scored 3.

### Group 6: bilateral incisions dividing a large part of the posterolateral columns

This group consisted of four patients, three females and one male. In one case there were large bilateral incisions in the posterolateral columns at C1 (Case 108, Fig. 8). This photograph does not delineate the area of damage clearly, as in addition to division of neural tissue there is a great deal of haemorrhage.

On the right, the incision divided almost all fibres of the lateral corticospinal tract and on the left about three-quarters of the fibres of the tract. It would have divided the rubrospinal tract bilaterally and many reticulospinal fibres in the lateral columns. The patient lived for 7 days after this operation in a precarious state, breathing being maintained by a respirator. Following the operation there was a total paralysis of all four limbs. Over 2–3 days she became able to move both lower limbs and regained minimal movements in the left upper limb. The right upper limb never recovered any movement. The patient could not move her body and could not speak, perhaps due to inability to influence respiration. It will be noted that she could not breathe spontaneously although the tracts for automatic respiration in the anterolateral funiculi were intact.

In another patient, Case 22 (Fig. 9), bilateral posterolateral incisions were made at T5. The Marchi preparations at T7 show that the entire lateral corticospinal tract was divided on the left. A comparison of the area of degenerating fibres within the area of the lateral corticospinal tract shows that on the right ~10–15% of fibres of the tract were not divided. The right incision divided fibres anterior to the lateral corticospinal tract;



**Fig. 9** Case 22. Marchi preparation at T7. Cordotomy at T5. Bar = 2 mm.



some were reticulospinal, but most were ascending, spino-cerebellar and spinothalamic.

For a few days after the operation, both lower limbs were flaccid, but within a week spasticity started to develop and over the ensuing months became very severe. It was equal in the two lower limbs. Movements of these limbs were slow and weak. There were increased stretch reflexes and clonus, increased flexion reflexes and flexor spasms, total paralysis of the small muscles of the feet and a bilateral Babinski response.

In general, when the motility of one lower limb was affected more than the other, it was always found post-mortem that the incision on the most affected side involved more of the posterolateral column than on the other side. Two cases illustrate this feature.

In Case 47, a bilateral cordotomy was carried out at T5 (Fig. 10). Within 24 h of the operation, there were full movements of the muscles of the right lower limb and the motility of this limb remained normal until the patient died. The incision on the right side of the cord, though large, divided the anterior quadrant of the cord. The muscles of the left lower limbs showed minimal contractions, insufficient to move any part of the limb. The incision on that side cut through the entire lateral corticospinal tract. By 3 weeks after the operation, she was able to stand, but she needed someone to support her on her left when she walked, as the limb frequently flexed. At that time all the muscles of the right lower limb scored 5, those of the left scored 3 or 4, except for the small muscles of the foot, which scored 2.

In Case 77 a bilateral cordotomy was carried out at T3-4 (Fig. 11). The anterior fibres of the lateral corticospinal tract on the right were divided; those on the left were intact, as the incision divided the anterior quadrant of the cord. Her ability to make circles with the left lower limb before and after the cordotomy is shown in Fig. 12. The circles were minimally less accurate after the operation, though this was within the limits of the normal. With the right lower limb, she was unable to do these movements after the cordotomy and so no record could be made.

### Recovery

The patient, Case 108, with very large bilateral incisions of the posterolateral funiculi at C1, could move three limbs by the end of the first week, but not the right upper limb.

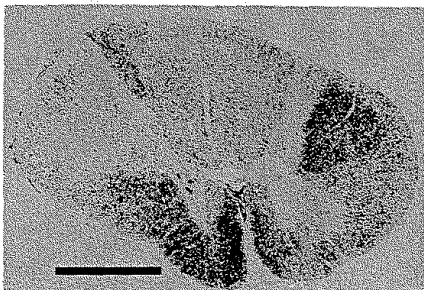


Fig. 10 Case 47. Marchi preparation. Cordotomy incisions at T5. Bar = 2 mm.

The patient with severe damage to the lateral corticospinal tract bilaterally at T5 (Case 22) eventually sat, stood and walked, but the clinical picture was that of severe spastic paraparesis. Indeed, the clinical recovery that had occurred in this patient was surprising, considering the amount of damage to these tracts subsequently seen post-mortem.

### General motor observations

Although impaired motility is considered under Groups 1-6 above, it should be remembered that motility depends not only on these long tracts taking origin in the brain but also on the long descending propriospinal fibres. Every incision into the spinal cord damages large numbers of these fibres. Most of them are motor fibres that facilitate both flexor and extensor reflexes.

### Sudden flexion of the lower limbs

After a unilateral or a bilateral cordotomy, the lower limbs might spontaneously flex while the patient was walking and the




Fig. 11 Case 77. Marchi preparation. Cordotomy incisions at T3-4. Bar = 2 mm.

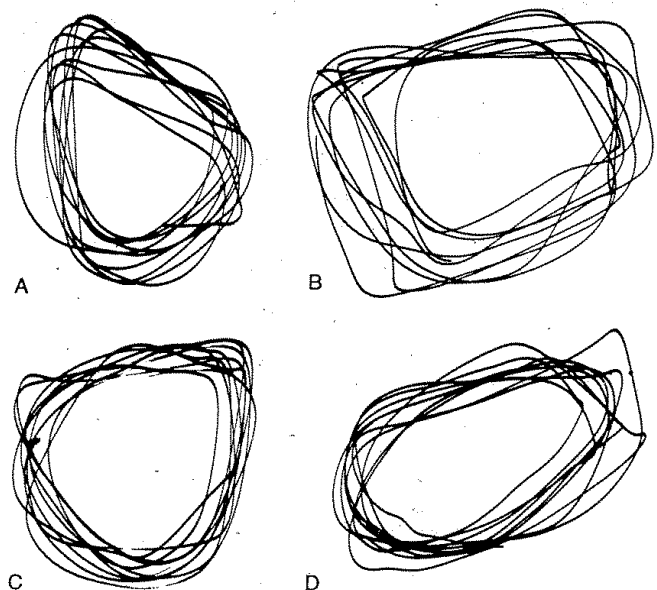


Fig. 12 Case 77. Traces of circular movements of left foot before and 148 days after cordotomy. A, clockwise before cordotomy. B, clockwise after cordotomy. C, anti-clockwise before cordotomy. D, anti-clockwise after cordotomy.

patient might fall. This disturbance of motility was not correlated with any form of stimulation, though it did occur in some cases when the subject stood after sitting for  $\frac{1}{2}$  h. It was unrelated to the flexion reflex associated with spasticity. It occurred with very small and superficial incisions as well as with large incisions. It was also unrelated to damage to the spinocerebellar tracts.

### *The plantar response*

The plantar response was frequently examined before and after cordotomy. To present all these observations in detail would be tedious and unrewarding. For one reason, the type of response usually changed between the time of operation and the patient's death: that fact alone shows that there is no correlation between the Babinski response and histological evidence of damage to the lateral corticospinal tract.

A normal response may become a Babinski response days or hours before the patient's death. This change was a part of diminution in strength of the lower limbs. Hours before death the plantar response was absent.

As the Babinski response is the least part of the disinhibited flexion reflex, a correlation was looked for between the Babinski response and the total flexion synergy associated with damage to the lateral corticospinal tract. About half of the patients with a Babinski response had increased flexion reflexes involving the whole limb. These patients also had decreased strength in the muscles of the peripheral part of the lower limbs.

A Babinski response may occur on the side opposite the cordotomy incision or it may be bilateral following a unilateral incision. In these cases, the pathological response lasted ~1 week and became normal as the patient got up and walked.

As the lateral corticospinal tract reaches far anteriorly in the cervical cord, the anterior part of the tract was commonly involved in the cervical cordotomies. This incision, however, was not usually associated with a Babinski response nor with other clinical signs considered to indicate corticospinal damage. On the other hand, there could be a normal response with post-mortem evidence of a large lesion of the lateral corticospinal tract. Large anterior incisions, whether unilateral or bilateral, were nearly always associated with a normal response, except during the first few days after the operation. One patient with very superficial incisions bilaterally in the lateral funiculus had a Babinski response bilaterally; it was still present 8 months after the operation, 10 days before death.

### **Conclusions**

The most surprising conclusion from these cases is that the anterior half of the cord can be divided below the cervical enlargement without any disturbance of motility of the trunk or lower limbs. This absence of defects was seen in four patients. In Case 51 (Fig. 5) this anterior bilateral operation was performed twice. In one of these cases, the lateral part of the incision came posterior to the equatorial plane. Thus, tracts in the anterior half of the cord deemed necessary for movements

of the lower limbs on the pelvis and for the essential control of the axial musculature can be divided below the cervical enlargement without causing the expected defects. It seems that the lateral corticospinal tract and perhaps reticulospinal tracts running posterior to the equatorial plane are adequate for carrying out the known functions of the tracts in the anterior half of the cord.

When there was some impairment of motility due to these anterior incisions, it was minimal. Deep reflexes might be diminished. One or two patients had a persistent feeling that they had to put more effort into a movement than normally.

The conclusions arrived at here, that the anterior columns can be divided with no or minimal disturbance of motility and that with posterolateral incisions there is maximal disturbance, apply also to each side of the cord and the ipsilateral lower limb. For instance, in Cases 47 (Fig. 10) and 77 (Fig. 11) there were no defects in motility in the lower limb on the side of the anterior incision and marked impairment on the side where the incision invaded the posterolateral column.

There were cases in which the damage to the anterior column was less than in Cases 47, 51 and 77 and yet there were defects in motility. In general, in these cords the incisions extended further posteriorly than in the cases in which there were larger but more anterior incisions. The total evidence leads to the conclusion that the more posterior to the equatorial plane the incision came, the greater were the defects in motility and the more likely were the patients to show spasticity and the reflex flexion synergy associated with paraparesis.

The patients in whom the incisions divided the tracts posterior to the equatorial plane bilaterally had such large incisions that they effectively had paraplegia below the incisions.

All incisions, except those restricted to the anterior columns, divided spinocerebellar fibres. There were no clinical symptoms or signs that could be attributed to division of these fibres.

The groups of fibres concerned with motor activity that were divided in these cases need to be considered. It might be thought that a diagram showing the location of the tracts would be helpful. But the evidence on this is inadequate. This impression is not given by textbooks of anatomy, where the diagrams are usually based on evidence in the cat or are a conglomerate derived from various species. From personal observations from studies in man, I would like to state the following general conclusions here. Tracts change their location in the cord and so the same incision at different cranio-caudal levels divides different fibre groups. Reticulospinal fibres are scattered in the anterior, anterolateral and lateral columns. Posteriorly, these fibres extend to the anterior border of the lateral corticospinal tract. The dorsal component of the lateral reticulospinal tract runs in this region. This assumes that the relationships are the same in man as the monkey. This is a motor tract and so is relevant to the cases reported here. However, in man there are also other reticulospinal fibres that descend immediately anterior to the lateral corticospinal tract, for reticulospinal fibres that enter the cord in the anterior and anterolateral columns move posteriorly as they descend—and so some fibres in the cervical enlargement and further caudally that are divided by a

large lateral or posterolateral incision are in the anterior and anterolateral columns further cranially (P. W. Nathan, unpublished observations).

### *Reorganization and recovery after paralysis*

The loss of movements after a large unilateral incision lasts only a matter of hours. In every unilateral cordotomy there was always some recovery of motility, no matter how large the incisions.

In Case 22, it was estimated that a total of 10–15% of lateral corticospinal fibres were intact on one side. This patient survived 154 days and was able to walk, although walking was impeded by clonus and flexor spasms. Whether recovery of motility in this and similar cases is due to the remaining lateral corticospinal tract fibres or to fibres in the lateral and anterior funiculi will be discussed below.

### *Correlation of signs of corticospinal tract damage and histological evidence of degeneration of lateral corticospinal tract fibres*

Clinical evidence of corticospinal lesions was correlated with evidence of damage to the lateral corticospinal tract post-mortem. The histological evidence consisted of descending degenerating fibres within the area of the lateral corticospinal tract caudal to the incision. In one bilateral case and in nine unilateral cases, it was forecast from the clinical evidence that the lateral corticospinal tracts would be found to be histologically unaffected. This was wrong, for in all of these cases there was some degeneration of the tract. In eight bilateral and six unilateral cases, it was forecast that the tract would probably be damaged. In all of these, this estimation was right. In one bilateral and eight unilateral cases, it was forecast that the tract would certainly be damaged. In all of these, this estimation was also right. But in one case it was anticipated that the tract would certainly be damaged; this was wrong. The overall conclusion is that any clinical evidence that the tract is involved or likely to be involved means that the tract is indeed damaged; but the tract can be damaged without any clinical evidence.

### *The plantar response*

Babinski (1903) insisted that his sign indicated a 'perturbation du fonction du système pyramidal' and stressed that it was a physiological and not an anatomical sign. This is certainly correct, as the Babinski response may occur with anoxia and with various drugs. However, an anatomical correlation is necessary to establish that there is a relationship between the abnormal plantar reflex and the state of the lateral corticospinal tract.

In 1955 Nathan and Smith concluded from the examination of the spinal cords of 38 cases of cordotomy that there was no particular relation between proved damage to the lateral corticospinal tract in the cord and the form of the plantar response. This conclusion was based on the presence of the

Babinski response in cases with histologically normal corticospinal tracts and cases with lesions of the anterior half of the spinal cord. That paper gave a misleading impression as no indication was given of the number of cases in each category and the total number of cases was small.

Conclusions are now based on 81 cases of cordotomy with histological examination of the cord. The accumulated evidence tends to support the classical tradition, i.e. that the Babinski response occurs with lesions of the lateral corticospinal tract and not with lesions elsewhere.

Since our previous paper (Nathan *et al.*, 1990), Dr Marion C. Smith has examined cases in which stereotactic lesions were made in the cerebrum for parkinsonism and other movement disorders. She found, in these patients, that a normal plantar response could occur with damage to the corticospinal tract and that the Babinski response could follow surgical intervention that divided motor pathways other than the corticospinal tract.

### **Discussion**

The purpose of this study is to correlate the motor state with the histologically verified lesion in the spinal cord. All those who study the effects of lesions within the central nervous system, including the author of this paper, like to assume that lesions of certain tracts are the only cause of the changes in motility that ensue. And yet one knows that the anatomical facts are only one factor and physiological factors are equally or more important.

In considering the effects of the operations on the cord, it may not be assumed that the results recorded here are the same as those that might ensue from dividing the same tracts at more cranial levels.

These observations can now be related to the results obtained and the problems encountered by other workers who carried out the same or related operations. Peet (1926) reported that in 19 cordotomies ('section of the anterolateral tracts') motility of the lower limbs was not affected.

Hyndman (1941) obtained the same results as we did. In his cases corresponding to our Group 3 (a unilateral incision dividing one anterior quadrant of the cord) and to Group 4 (a bilateral incision dividing the anterior half of the cord), there was complete recovery of all motor function within a few days of the operation. We thus concur with his conclusion, that it appears that in man the posterior columns and pyramidal tracts have superseded almost completely the extrapyramidal tracts in the anterior part of the cord'.

Very large incisions into the spinal cord were made by Ebin (1949) in 11 cases of parkinsonism. The purpose of the operation was to cut the lateral corticospinal tract of one side and the anterior corticospinal tract of the other. The incisions were made at C4 or C5 so as to affect both the upper and lower limbs. This 'combined lateral and ventral pyramidotomy' was followed by recovery of 'voluntary movement', varying in the different cases from 20 to 90%. In fact, these incisions divided not only the corticospinal tracts as intended, but also a part of the spinothalamic tract, lying anterior to the lateral corticospinal



tract and therefore they also divided reticulospinal fibres anterior to the lateral corticospinal tract. On the side contralateral to the divided lateral corticospinal tract they divided the medial part of the anterior column. Although his diagrams illustrate very large bilateral incisions into the cord, dividing both lateral corticospinal tracts, the lateral reticulospinal fibres and the rubrospinal tracts at C5-6, the incisions left almost the entire anterior half of the cord intact. There were great variations in the results of these operations. It is hazardous to draw any conclusions without post-mortem evidence of the location and extent of the surgical incisions. One might conclude, that without this evidence, the motor recovery was due to tracts of the anterior half of the cord remaining intact or almost intact.

The anterior cordotomies reported here, those of Peet (1926) and Hyndman (1941), our case with large surgical lesions of the lateral corticospinal tract in the thoracic cord and the surgical divisions of the corticospinal tracts in the cervical cord (Ebin, 1949) once again bring up questions about the possible role of corticospinal tracts in the recovery that ensues after lesions of motor tracts.

Bucy *et al.* (1964) also divided corticospinal tracts to relieve parkinsonism, and so he too found himself faced with the problem of the contribution to motility of the corticospinal tracts. In this paper they demonstrated the good recovery that occurred when the corticospinal tract was divided in one peduncle. By 7-8 months, movements of limbs contralateral to the incision 'were strong, useful and well coordinated'. In the divided peduncle 'only 17% of the corticospinal fibres remained intact'. As Bucy wrote to Dr Marion Smith and me: 'This bothered me and like others I, too, wonder if this 17% might be responsible for the recovery of movement which this man experienced. However, the 17% of persisting fibers were in that part of the cerebral peduncle which Kuypers showed to be projected primarily to sensory neurons in the spinal cord.' It was on account of this 17% of remaining fibres that Bucy decided to divide the corticospinal fibres in the monkey. In 1966 Bucy *et al.* reported the effects of dividing both corticospinal tracts in the peduncles in that species. Ultimately, the animals walked and climbed. Thus this work showed that pathways other than the corticospinal tracts allowed the animals to regain good motor function, so that motility was eventually normal or a little less than normal. Since that time, other workers have divided the corticospinal tracts in the monkey and have obtained the same results as Bucy and colleagues.

Subsequently, Jane *et al.* (1968) divided the corticospinal tract in man by cutting through the middle third of the peduncles. They performed this operation bilaterally in two patients and unilaterally in 12. Follow-up was from 1 to 2 years. Apart from minimal weakness, there were no motor defects, except following one of the bilateral operations. They concluded that: 'In man recovery of motor function including fine distal movement is compatible with complete section of the middle third of the peduncle and subsequent degeneration of 83% of the pyramidal fibers.' It is likely that their division of the middle third of the peduncles would have cut through corticospinal fibres, including those originating in the pre-motor cortex area

FB (Minckler *et al.*, 1944). 'Fine distal movement' presumably means skilled movements of the digits of the upper limb. These movements can only be performed with intact corticospinal fibres, and so in their cases it can be concluded that these movements were possible on account of corticospinal fibres that remained.

In 1973 Nathan and Smith reported that any recovery of motility of the lower limb ensuing upon an incision involving one lateral corticospinal tract was immediately removed by a large incision of the opposite lateral corticospinal tract; if any recovery occurred after the second operation, this was always associated with lateral corticospinal fibres being intact. We concluded that the recovery that occurred after the division of one lateral corticospinal tract was due to conduction in the opposite tract and further, as recovery occurred so quickly, we proposed that the opposite lateral corticospinal tract was having bilateral effects before the first cordotomy. This conclusion may be extended to the upper limbs, for it would be difficult to account in any other way for the immediate recovery that occurs after an incision as large as that shown in Case 80 (Fig. 2). Nevertheless the functioning of the opposite lateral corticospinal tract is not a substitute for the divided tract, for if it were, hemiplegia would not exist.

### Acknowledgements

I wish to thank the many neurosurgeons and neuropathologists who sent material to Dr Marion C. Smith and myself for our investigations related to pain-relieving operations on the spinal cord; Ms Pat Deacon for many years' help in our work; Mr W. Bessant and Stephen Durr for their photographic work; Dr Ricardo de Oliveira Souza, Professor Ruth Bowden and G. D. Schott for helpful discussions. I also wish to thank members of the Department of Neuropathology of the Radcliffe Infirmary, Oxford, for giving me laboratory facilities. Most of this work was undertaken when the author was a member of the External Scientific Staff, Medical Research Council, National Hospital for Neurology and Neurosurgery, Queen Square, London.

### References

- Babinski J. De l'abduction des orteils. *Rev Neurol (Paris)* 1903; 11: 728-9.
- Bucy PC, Keplinger JE, Siqueira EB. Destruction of the 'pyramidal tract' in man. *J Neurosurg* 1964; 21: 385-98.
- Bucy PC, Ladpli R, Ehrlich A. Destruction of the pyramidal tract in the monkey. The effects of bilateral section of the cerebral peduncles. *J Neurosurg* 1966; 25: 1-23.
- Ebin J. Combined lateral and ventral pyramidotomy in treatment of paralysis agitans. *Arch Neurol Psychiatry* 1949; 62: 27-47.
- Hyndman OR. Physiology of the spinal cord. 1. Role of the anterior column in hyperreflexia. *Arch Neurol Psychiatry* 1941; 46: 695-703.
- Jane JA, Yashon D, Becker DF, Batty R, Sugar O. The effect of

destruction of the corticospinal tract in the human cerebral peduncle upon motor function and involuntary movements. Report of 11 cases. *J Neurosurg* 1968; 29: 581–5.

Medical Research Council. Aids to the investigation of peripheral nerve injuries. Medical Research Council War Memorandum No. 7. Rev 2nd ed. London: Her Majesty's Stationery Office, 1943.

Minkler J, Klemme RM, Minkler D. Course of efferent fibres from human premotor cortex. *J Comp Neurol* 1944; 81: 259–77.

Nathan PW, Smith MC. The Babinski response: a review and new observations. *J Neurol Neurosurg Psychiatry* 1955; 18: 250–9.

Nathan PW, Smith MC. Effects of two unilateral cordotomies on the motility of the lower limbs. *Brain* 1973; 96: 471–94.

Nathan PW, Smith MC, Deacon P. The corticospinal tracts in man. Course and location of fibres at different segmental levels. *Brain* 1990; 113: 303–24.

Peet MM. The control of intractable pain in lumbar region, pelvis and lower extremity by section of the anterolateral columns of the spinal cord (cordotomy). *Arch Surg* 1926; 13: 153–204.

*Received June 24, 1993. Revised December 9, 1993.*

*Accepted December 21, 1993*